



# Histopathological Spectrum of Urinary Bladder Lesions in Patients at the Sirte Oncology Center

Habsa A. A. Amshahar<sup>1</sup>, Fatima Alssadi<sup>2</sup> and Mohammed A. M. Amshaheer<sup>3</sup>

<sup>1</sup> Pathology Department, Faculty of medicine, Sirte University, Sirte, Libya.

<sup>2</sup> Pathology Department, Sirte Oncology Center, Sirte, Libya.

<sup>3</sup> Faculty of medicine, Sirte University, Sirte, Libya.

© SUSJ2022.

## A B S T R A C T

DOI: [10.37375/susj.v14i2.3086](https://doi.org/10.37375/susj.v14i2.3086)

### ARTICLE INFO:

Received 8 October 2024.

Accepted 26 November 2024.

Available online 24 December 2024.

**Keywords:** Urinary bladder lesions, Neoplastic, Non neoplastic, Papillary urothelial carcinoma.

**Introduction:** There are various common non neoplastic and neoplastic (benign and malignant) lesions of urinary bladder. They are common causes for worldwide morbidity and mortality. This study aimed to study the histopathology spectrum of different urinary bladder lesions. **Material and Methods:** The current retrospective study included all reported cases of the received urinary bladder specimens in pathology department at Sirte Oncology Center. **Results:** Majority of 49 studied cases were males (87.8%). Out of which, 67.4% were neoplastic lesions with predominance of invasive urothelial tumors (63.6%), whereas 28.6% of cases were non neoplastic lesions. Inflammatory lesions (78.6%) formed the bulk amongst the non neoplastic lesions. **Conclusion:** The present study showed male predominance with the most encountered urinary bladder lesions are neoplastic lesions of urothelial origin. The majority of urothelial tumor are invasive cancer than non invasive type of urothelial carcinoma.

## 1 Introduction

Urinary bladder lesions includes neoplastic and non neoplastic lesions. The incidence of both lesions has been increasing recently worldwide<sup>1</sup> and they are known cause for both morbidity and mortality<sup>2</sup>. The most common non neoplastic lesion is cystitis<sup>3</sup>, although, are usually not lethal, however they deteriorate the quality of life. Additionally, there are many reactive, metaplastic, hyperplastic and proliferative bladder lesions which may occurs in response to chronic irritation processes and should be recognized from malignant processes<sup>4</sup>. The most common neoplastic lesion is urothelial carcinoma accounting 90% of all primary tumors of the urinary bladder<sup>5</sup>. Generally, the bladder cancers accounts for 3% of all cancer diagnosis and is 11<sup>th</sup> most common cancer globally<sup>6</sup>. There are

many factors strongly associated with increased risk for bladder cancers such as the cigarette smoking, environmental and occupational factors<sup>7 8 9</sup>. Histological grading and staging of cancer are very important prognostic parameters, so it is critical to include muscle in biopsied tissue to assess presence of invasion<sup>10</sup>. An accurate diagnosis of various urinary bladder lesions requires clinical, radiological and histologic evaluation<sup>11 12</sup>. Sri kousthubha et al showed that, the cystoscopy and proper urinary bladder biopsies are the mainstay for diagnosis urinary bladder lesions<sup>13</sup>. So they consider the first line investigation for urinary bladder lesions with clinico-radiological features of bladder mass or diffuse thickening of urinary bladder wall, and further histopathological evaluation is important to diagnose and categorize the non neoplastic conditions and neoplastic lesions and for planning of patient

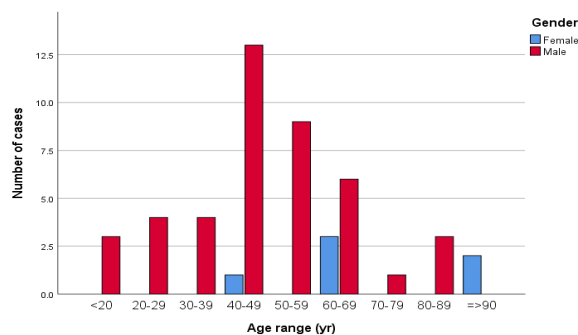
management<sup>13</sup>. There was no study done in Libyan patients in Sirte city at middle region of Libya about neoplastic and non neoplastic urinary bladder lesions, and categorization of the bladder neoplasms according to the recent updates. Therefore, our aim in the current study is to study histopathological spectrum of different urinary bladder lesions in a sample of Libyan population from Sirte Oncology Center located in Sirte city.

## 2 Materials and Methods

A cross-sectional retrospective study was performed in the department of pathology at Sirte Oncology Centre during period from October 2021 to January 2024. It includes 49 cases of transurethral resection of bladder tumor (TURBT) and radical cystectomy specimens that were received in the pathology department. Their pathology reports were retrieved and reviewed by histopathologist to confirm the diagnosis, and the lesions were classified neoplastic and non neoplastic, and further classification and staging of neoplastic lesions based on WHO classification and AJCC staging respectively<sup>14 15</sup> were performed. Any cases with ambiguous diagnosis or incomplete demographic data were excluded from the study. Data was analyzed using SPSS version 26.0 statistical software, where simple univariate and multivariate analyses were performed to assess the sex and age distribution of urinary bladder lesions and subdivision of the bladder lesions with estimation of numbers and percentages, and for descriptive statistics of the mean and range were used to describe central tendency and dispersion.

## 3 Results

Among the 49 total cases in the study, 43 (87.8%) were males and 6 (12.2%) were females. The age of the studied cases ranged from 15 to 94 years, and the mean age was 58 years. Peak incidence was in the age group 40-49 years (28.6%), as seen in Figure 1.



**Figure 1.** Distribution of cases according to the gender and age groups.

The majority of the cases who had undergone bladder TURBT and cystectomy had neoplastic lesions constituting 67.4%, while 28.6% (14 cases) had non-neoplastic lesions, and 2% (1 case) had normal histology and 2% was non-diagnostic (Table 1).

**Table 1.** Histopathological diagnosis wise distribution of cases.

Histopathological diagnosis	No. of cases (%)
Non neoplastic	14 (28.6%)
Neoplastic	33 (67.4%)
Normal histology	1 (2%)
Non diagnostic	1 (2%)
<b>Total</b>	<b>49 (100%)</b>

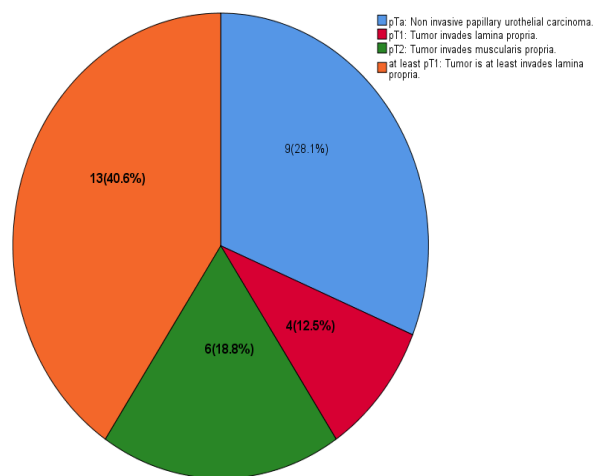
Table 2 showed that neoplastic lesions (33 cases) included mainly of urothelial tumors (31 cases (93.9%)) and squamous cell neoplasm of the urinary tract (2 cases (6.1%)). The majority of cases with urothelial tumor reported as invasive papillary urothelial carcinoma, low grade (33.3%) followed by invasive papillary urothelial carcinoma, high grade (30.3%). Both comprising 67.7 % (21/31 cases) of the urothelial tumors, further more invasive papillary carcinoma comprised 63.6% (21/33 cases) of all neoplastic lesions, while the least encountered urothelial lesion was urothelial papilloma comprised 3% of neoplastic lesions.

**Table 2.** Histopathological diagnosis of neoplastic lesions among the study population.

Histopathological diagnosis	No. of cases (%)
<b>Neoplastic lesions</b>	
<b>Urothelial tumors</b>	<b>31 (93.9%)</b>
a. Noninvasive urothelial tumors	10 (30.3%)
- Urothelial papilloma	1 (3%)
- Noninvasive papillary urothelial carcinoma, low grade	9 (27.3%)
b. Invasive urothelial neoplasms	21 (63.6%)
- Invasive papillary urothelial carcinoma, low grade	11 (33.3%)
- Invasive papillary urothelial carcinoma, high grade	10 (30.3%)
<b>Squamous cell neoplasms of the urinary tract</b>	<b>2 (6.1%)</b>
Squamous cell carcinoma of the urinary tract	2 (6.1%)

<b>Total</b>	<b>33 (100%)</b>
--------------	------------------

Additionally, pathological staging was rendered in all malignant cases (32 cases) (Figure 2), which had been diagnosed as noninvasive papillary urothelial carcinoma low grade, invasive urothelial carcinoma low and high grade, and squamous cells carcinoma. Noninvasive papillary urothelial carcinoma (pTa) was found in 9 (28.1%) cases while lamina propria invasion (pT1) was observed in 4 (12.5%) cases, followed by pT2 with tumors invading into muscularis propria observed in 6 (18.8%) cases. There were no reported cases with TNM staging of pT3 or pT4 identified. In addition, there was no muscle included in 13 (40.6%) of cases and TNM staging was reported as at least pT1. TNM staging was not done in one noninvasive tumor/ benign lesion of urothelial papilloma (3%). Among the patients with neoplastic lesions, 87.87 % were males and 12.12% were females, most of the cases (11/33) i.e. 33.33% belonged to the age group 40-49 years.



**Figure 2.** Pathologic staging of malignant cases (n=32).

The most common non neoplastic lesion made in the current study was eosinophilic cystitis (4 cases). Of the 14 non neoplastic cases, 11 cases (78.6%) were diagnosed with inflammatory lesions, 1 case (7.14%) came under the category of tumor like lesions and 2 cases (14.29%) came under the category of epithelial abnormalities. Among the 11 inflammatory lesions, 4 cases (28.6%) were of eosinophilic cystitis, 3 cases (21.42%) were of chronic non-specific cystitis (polypoid type) and 3 cases (21.42%) were of chronic diffuse cystitis and one case (7.14%) was of follicular cystitis.

In our study, eosinophilic cystitis was the commonest form of cystitis. 1 case of tumor like lesions diagnosed as an inflammatory pseudo tumor. 2 cases of epithelial abnormalities included 1 case each of cystitis glandularis and squamous metaplasia (Table 3).

**Table 3.** Histopathological diagnosis of non neoplastic lesions among the study population.

Histopathological diagnosis	No. of cases (%)
<b>Non neoplastic lesions</b>	
<b>- Inflammatory lesions</b>	<b>11 (78.6%)</b>
Chronic non-specific cystitis (polypoid type)	3 (21.42%)
Follicular cystitis	1 (7.14%)
Eosinophilic cystitis	4 (28.6%)
Chronic diffuse cystitis	3 (21.42%)
<b>- Tumor like lesions</b>	<b>1 (7.14%)</b>
Inflammatory pseudo tumor	1 (7.14%)
<b>- Epithelial abnormalities</b>	<b>2 (14.29%)</b>
Cystitis glandularis	1 (7.14%)
Squamous metaplasia	1 (7.14%)
<b>Total</b>	<b>14 (100%)</b>

#### 4 Discussion

A total of 49 cases were studied, bladder lesions were predominantly encountered in male patients (87.8%), this consistent with other results of studies done by Poudel et al, Lashiram et al and Roshed et al<sup>16 17 18</sup>. The former result may be related to occupational exposure and habitual facts in males<sup>19</sup>. The mean age of cases at time of diagnosis was in agreement with other study<sup>17</sup>. In the present study, majority of the urinary bladder lesions diagnosed in fourth decade of life, this concordant with study was performed for urinary bladder cancer where cancer cases detected in age category 40 years and above<sup>20</sup>. In the recent study, the neoplastic lesions was diagnosed at age of 40 years and above and the neoplastic lesions were predominate in studied sample and could be reflecting on the overall age category for total urinary bladder lesions. On other hand, our finding was inconsistent with other observations where most of the cases of bladder lesions were in age range of 60-80 years<sup>21 16</sup>, and other studies where the age of presentation was sixth decade of life<sup>22 23</sup>. In the current study, the vast majority of the urinary bladder lesions were attributed to neoplastic lesions (67.4% (33 cases)) and the remaining cases were found to be non

neoplastic (28.6% (14 cases)) while cases reported with normal histology and non-diagnostic cases each comprising 2% of total cases (Table 1), this consistent with other studies<sup>13 16</sup>. The neoplastic lesions found to be tumor of epithelial origin, of which, the majority were arising from the urothelial line the bladder (31/33 cases (93.9%)) (Table 2), this concordant with other reporters<sup>24 25 26</sup>. Invasive urothelial neoplasms were the most common type of neoplasms, it constituted 67.7% (21/31) of cases with urothelial tumors and 63.6% (21/33 cases) of all neoplastic cases, of which invasive papillary urothelial carcinoma, low grade (33.3%) were found to be the commonest diagnosis, followed by invasive papillary urothelial carcinoma, high grade (30.3%) (Table 2), these findings concordant with other study done by Naeima A,S.AL Agori et al and Susmitha et al, showed the invasive urothelial carcinoma constituted 48.72% (19/39 cases) and 60.71% (17/28 cases) respectively<sup>25 27</sup>, and discordant with other performed study found that, the majority of tumor cases were reported as noninvasive urothelial neoplasms (21/24 cases (87.5%))<sup>13</sup>. In our study, the noninvasive urothelial neoplasms constituted 32.3% (10/3 cases) of urothelial tumor cases and 30.3% (10/33 cases) of all neoplastic lesions, and they include 9 (27.3%) cases of low grade papillary urothelial carcinoma and one case (3%) of urothelial papilloma (Table 2). Among urinary bladder lesions, urothelial papilloma was less frequently encountered lesion consistent with study done by Thapa et al<sup>28</sup>. In view of grade of invasive cancer, the majority of currently studied cancer cases were of low grade as illustrated in table 3. This finding consistent with studies were done by Thapa et al and Mainali et al revealed majority of invasive carcinoma were a low grade accounting for 50% and 49.2% respectively of their reported cases<sup>28 29</sup>, however, other study demonstrated the invasive tumor was a high grade (30.91%)<sup>16</sup>. Pathologic staging of cancer cases is very important for prognosis and treatment plan<sup>30</sup>. In the current study, 4 (12.5%) cases of invasive papillary urothelial carcinoma showed invasion into lamina propria (pT1) while 6 (18.8%) cases showed tumor invading into muscularis propria (pT2) (Figure 2), other authors showed 7 (25%) cases showing invasion into lamina propria and 10 (35.71%) cases having invasion into muscularis propria<sup>27</sup>. The presence of smooth muscle in the biopsy is very important for accurate grading and staging<sup>1</sup>. In the present study, the inflammatory lesions (Table 3) were the most commonly encountered lesions (78.6%) particularly eosinophilic cystitis constituted 28.6% (4/14cases) followed by chronic non-specific cystitis (polypoidal type) and chronic diffuse cystitis each comprising 21.42% of total cases, the former is

incompatible to other study found chronic non-specific cystitis to be the commonest inflammatory lesions<sup>13</sup>. Presence of striking eosinophilic infiltrate could be associated with allergic diseases or associated with bladder injuries without presence of allergy<sup>31</sup>. In the recent study, there was one case of tumor like lesions reported as an inflammatory pseudo tumor (Table 3), consistent with other study<sup>13</sup>. Our study showed also one case of squamous metaplasia and one case of cystitis glandularis (Table 3), these findings of epithelial abnormalities concordant with other observation<sup>13</sup>, and may occurs in response to inflammatory process of chronic irritations and is important to differentiate from other similar malignant lesions<sup>32 33</sup>. It should be considered that, the current study has limitations including the sample size over the study period and unavailability of data for some variables where data collected during early establishment of the center, in addition to superficial tissue sampling, however, the recent study added to present knowledge about urinary bladder lesions encountered in the Libyan population. The author emphasis on doing further studies focusing on bladder cancer in the Libyan population.

## 5. Conclusions

In this study, urinary bladder lesions showed male predominance. The neoplastic lesions were more common than non neoplastic lesions. Most of the neoplastic lesions were of urothelial origin and invasive urothelial carcinoma formed the bulk of the neoplastic lesions, comprising a low grade invasive cancer followed by a high grade invasive cancer. Amongst the non neoplastic lesions, a majority were of inflammatory origin, however, epithelial abnormality and tumor like conditions mainly inflammatory pseudo tumors were also encountered.

## Acknowledgements

The authors acknowledge Pathology Department at Sirt Oncology Centre for their co- operation.

**Conflict of interest:** Authors declare that there are no potential conflicts of interest.

## References

1. Dravid N. Histomorphological profile of lesions in cystoscopic bladder biopsies - a prospective study in North Maharashtra. *International journal of clinical and experimental pathology*. 2016;3:161–166.
2. Matalka I, Bani-Hani K, Shotar A, Bani Hani O, Bani-Hani I. Transitional cell carcinoma of the urinary bladder: a clinicopathological study. *Singapore Med J*. 2008;49(10):790–794.
3. Priya K, Bharti RR, Kumar D, Atreya K, Kumar B. A study on histopathological spectrum of lesions in urinary bladder specimens in tertiary center in Bihar. *European Journal of Molecular and Clinical Medicine*. 2022;9(3):750–759.
4. Harik LR, O'Toole KM. Nonneoplastic lesions of the prostate and bladder. *Arch Pathol Lab Med*. 2012;136(7):721–734.
5. Kumar M, Yelikar BR. Spectrum of Lesions in Cystoscopic Bladder Biopsies-A Histopathological Study. *Al Ameen J Medical Sci*. 2012;(5):132–6.
6. Saginala K, Barsouk A, Aluru JS, et al. Epidemiology of Bladder Cancer. *Medical Sciences*. 2020;8(1):15.
7. Prout GR, Barton BA, Griffin PP, Friedell GH. Treated History of Noninvasive Grade 1 Transitional Cell Carcinoma. *The Journal of Urology*. 1992;148(5, Part 1):1413–1419.
8. Pagano F, Bassi P, Galetti TP, et al. Results of Contemporary Radical Cystectomy for Invasive Bladder Cancer: A Clinicopathological Study With an Emphasis on the Inadequacy of the Tumor, Nodes and Metastases Classification. *The Journal of Urology*. 1991;145(1):45–50.
9. Jhaveri PN, Makwana SV, Oza KK, Shah CK. A histopathological study of urinary bladder neoplasms. *Indian J Pathol Oncol*. 2021;8(1):59–63.
10. Modi MB, Merja MR, Shah NR, Nilkanthe RG. Study of grading and staging of bladder carcinoma in transurethral resection of urinary bladder. *Archives of Cytology and Histopathology Research*. 2016;1(1):21–27.
11. Amin MB. APII Urinary bladder biopsy interpretation part-1. *College of American pathologists*. 2004;
12. Grignon D J. Neoplasms of the Urinary Bladder. *Urologic Surgical Pathology*. 1997;215–305.
13. Raghuvveer CV, Hingle S. Profile of lesions in cystoscopic bladder biopsies: a histopathological study. *Journal of Clinical and Diagnostic Research: JCDR*. 2013;7(8):1609.
14. Board WC of TE. WHO Classification of Tumours of the Urinary System and Male Genital Organs. 5th Ed. IARC: Lyon; 2022.
15. Bochner BH, Hansel DE, Efstathion JA, Konety B, Lee CT, Mckiernan JM, et al. Urinary Bladder. In: Amin M.B. (eds). *AJCC Cancer Staging Manual*. 8th Ed. Springer nature; USA. 2018;. Pp.765–74.
16. Poudel S, Ranabhat S, Shahi S, Pun G. Spectrum of Lesions in the Urinary Bladder: A Histopathological Study in a Tertiary Level Hospital. *Journal of College of Medical Sciences-Nepal*. 2023;19(3):307–312.
17. Roshed MM, Ahmed M, Ali M. Histomorphological pattern of urinary bladder mass with their clinical correlation. *Bangladesh Medical Journal Khulna*. 2021;54(1–2):3–7.
18. Laishram RS, Kipgen P, Laishram S, Khuraijam S, Sharma DC. Urothelial tumors of the urinary bladder in Manipur: a histopathological perspective. *Asian Pac J Cancer Prev*. 2012;13(6):2477–9.
19. Jhaveri PN, Makwana SV, Oza KK, Shah CK. A histopathological study of urinary bladder neoplasms. *Indian J Pathol Oncol*. 2021;8(1):59–63.
20. Kundra M, Hemapant. Urinary Bladder Tumors: A comparative histopathological study in patients less than 40 years and more than 40 years. *Indian Journal of Pathology and Oncology*. 2017;4(4):507–510.
21. Paudel D, Regmi H, Bajracharya U, Shrestha GK. Spectrum and presentation of urinary bladder growth: a single-center retrospective study. *Nepalese Medical Journal*. 2021;4(2):485–488.
22. Shah A, Srivastava M, Samdurkar A, Sigdel G. SPECTRUM OF LESIONS IN URINARY BLADDER-A HISTOPATHOLOGICAL STUDY. *Journal of Universal College of Medical Sciences*. 2018;6(2):.
23. Pokar R, Parsana R. Spectrum of histopathological variants in urinary bladder carcinoma-Experience in a tertiary care hospital. *IP Archives of Cytology and Histopathology Research*. 2023;7(4):237–240.
24. Reuter VE. BLADDER: Risk and Prognostic Factors—a Pathologist's Perspective. *Urologic Clinics of North America*. 1999;26(3):481–492.
25. Hend RAA, Naeima ASA-A, Manal FY, et al. Urinary Bladder Cancer-Epidemiological and Histopathological Study. *International journal of multidisciplinary research and analysis*. 2023;06(03):1195–1201.
26. Shrestha AN, Regmi A, Rana A, et al. Histomorphological pattern of lesions of cystoscopic bladder biopsies in a tertiary center in Nepal-A retrospective descriptive study. *Journal of Pathology of Nepal*. 2022;12(2):1913–1916.
27. S S, Patil GS, Patil SB. A Study on Histopathological Spectrum of Lesions in Urinary Bladder Specimens. *Annals of Pathology and Laboratory Medicine*. 2018;5(6):A489-495.
28. Thapa R, Lakhey M, Bhatta AD. Spectrum of histomorphological diagnosis in cystoscopic bladder

- biopsies. *Journal of pathology of Nepal*. 2017;7(1):1062–1065.
29. Mainali N, Chaudhary P, Nepal N, Shrestha J. Spectrum of Urothelial lesions in Cystoscopic biopsies: A Histopathological Perspective. *Journal of Nobel Medical College*. 2018;7(1):6–10.
30. Cheng L, Montironi R, Davidson DD, Lopez-Beltran A. Staging and reporting of urothelial carcinoma of the urinary bladder. *Modern Pathology*. 2009;22:S70–S95.
31. Reuter VE et al. *The lower urinary tract: Silverberg's Diagnostic Surgical Pathology*, second edition. New York: Raven Press Ltd. 1994;
32. Manini C, Angulo JC, López JI. Mimickers of urothelial carcinoma and the approach to differential diagnosis. *Clinics and Practice*. 2021;11(1):110–123.
33. Black AJ, Black PC. Variant histology in bladder cancer: diagnostic and clinical implications. *Translational cancer research*. 2020;9(10):6565.