
Replenishing effect of dehydroepiandrosteron on the ovary toxicity induced by exposure to vinylcyclohexene diepoxide in mature female rats***Adel A. Elbadry******Salah F. Kamies*******Nura I. Al-Zail**

Abstract: Administrations of dehydroepiandrosterone (DHEA) to female had effects on ovarian response ovarian reserve, oocytes embryo yield quality, cumulus pregnancy rate, live birth rate and also improved the miscarriage rate and improve the results of infertility treatment. The aim of present study is to examine the replenishing effect of dehydroepiandrosterone (DHEA) on the reprotoxicity induced by exposure to vinylcyclohexene diepoxide (VCD) on mature female rats. 48 mature female rats were divided into equal four groups. The control group was injected intraperitoneally with sesame oil (0.2 ml) daily for 45 days. The second group was injected with DHEA (0.2 ml) once daily for 45 days. The third group was injected with VCD (1.2 ml) once daily for 45 days. The fourth group was injected with DHEA (0.2 ml) +VCD (1.2 ml) once daily for 45 days. Results showed that the DHEA treated females was close to the control rats in most of the measured plasma hormone levels, except DHEA and CORT hormones. While the group treated with VCD recorded a significant decrease ($P<0.05$) in most of the hormones (P4, E2, FSH, LH, INS and DHEA) except the CORT hormone. It should be noted that the gradual improvement that occurred as a result of giving DHEA to females treated with VCD in the levels of all hormones as compared with control rats. Histopathological examination of female rat ovaries in VCD group showing atrophied primordial follicle with pyknotic nuclei. DHEA group reveals normal primordial follicle with owl eye nuclei. DHEA+VCD group revealing normal primary follicle with owl eye nuclei. From present study it could be concluded that administration of DHEA to female rat affecting on reproductive function, it is important precursor steroid to synthesis of the sex steroid and is changed to androgens or estrogens. The estrogens stimulate the ovaries and increase growth of the follicles and proliferation of granulosa cell and development.

Key words: Dehydroepiandrosterone, Vinylcyclohexene diepoxide, Reproductive system, Sexual hormones, Female rat.

*** Department of Physiology, Faculty of Veterinary Medicine, Zagazig University, Egypt**

**** Department of Physiology, Faculty of Veterinary Medicine, Omar AL-Moukhtar University, El-Beida, Libya**

***** Department of Zoology, Faculty of Science, Omar AL-Moukhtar University, El-Beida, Libya.**

Corresponding Author: Nura I. Al-Zail, Department of Zoology, Faculty of Science, Omar AL-Moukhtar University, El-Beida, Libya . [E.mail/nurazail1982@gmail.com](mailto:nurazail1982@gmail.com)

Introduction

Regulation of the reproductive axis begins at the level of the hypothalamus, where neurosecretory cells synthesize and release gonadotropin releasing hormone (GnRH) into the hypothalamic-hypophyseal-portal circulation. Gonadotrophs in the anterior pituitary synthesize and release the gonadotropins Follicular stimulating hormone and luteinizing hormone (FSH and LH) that control the gonadal functions (**Auchus, 2004**). FSH stimulates follicular growth, inhibin and estrogen synthesis while LH induces ovulation and corpus luteum functions including progesterone synthesis (**Ahn et al, 2012**).

Dehydroepiandrosterone (DHEA) is a naturally occurring steroid hormone produced by the adrenal glands, whose levels decline rapidly with age. DHEA serves as an indirect precursor to estrogen and testosterone (**Hashimoto, 2013**). Androgens are 19-carbon steroid compounds that are synthesized from cholesterol. The 4 major androgens present in the systemic circulation are dehydroepiandrosterone (DHEA; mostly as DHEA sulfate), androstenedione, testosterone, and 5 α -dihydrotestosterone (5 α -DHT). Androstenediol is a 5th androgen that is produced in lesser amounts (**Labrie et al, 2017**).

It also is important to note that androgens are the necessary precursors for the biosynthesis of estrogens. In the ovaries, adrenal gland, and peripheral tissues, DHEA and androstenedione can be converted to testosterone, which in turn can be converted to the more potent androgen 5 α -DHT by the action of 5 α -reductases or to estradiol by aromatase (**Thomas et al., 2018**).

DHEA administration causes increasing levels of FSH receptors at early stages of folliculogenesis and thus it is benefit for follicle recruitment and development which is confirm by the significant increase of serum FSH level after DHEA administration. According to the two cell-two gonadotrophin theory, the androgens levels play an essential and important role in ensuring adequate follicular steroidogenesis. At this meantime, DHEA is considered as crucial precursor steroid to the sex steroid synthesis and is changed to androgens or estrogens. The estrogens promote ovarian and increase the follicular growth and granulosa cell proliferation and development the estradiol concentration shows and explain a significant increase in rats received DHEA (**Sunkara et al., 2012**).

Vaginal perfusion also is regulated by androgens and estrogens in the context of baseline blood flow and during sexual arousal. In postmenopausal women, esterified estrogens increased genital blood flow, administration of testosterone or estradiol in ovariectomized rats restored vaginal blood flow due to pelvic nerve stimulation (**Tan et al., 2012**).

Specific mechanisms characterized, testosterone and estradiol regulate nitric oxide synthase and arginase expression, key proteins regulating vaginal blood flow, vaginal vasocongestion and genital sensation in response to visual sexual stimulation was significantly increased 3 to 4.5 hours after sublingual administration of testosterone undecanoate (**Gandhi et al., 2016**).

DHEA supplementation had effects on ovarian response ,ovarian reserve ,oocytes embryo yield quality ,cumulus pregnancy rate live birth rate and also improved the miscarriage rate in women with poor ovarian response (POR), biochemical and ultrasound parameters FSH, estradiol, AMH, and antral follicle count (AFC) and treatment outcomes (count of oocytes retrieved, Day3 embryos and transferred embryos) all ameliorated significantly following DHEA supplementation (**Tsui et al., 2014**).

Diminished ovarian reserves (DOR) commonly reported on the very low egg supply, which is the most common causes of infertility in animals and women. Also, the decreased DHEA levels can cause the DOR condition, the DHEA is commonly used primarily to treat women with DOR which occurs either as a results of female aging or premature ovarian aging (POA). DHEA is used in menopause females which is usually associated with a sudden decline in estrogen one, in order to overcome infertility and improve the live birth rate, attention has been increased at the last few years to involve DHEA (an endogenous of adrenal steroid from the ovarian theca cells and adrenal cortex) which is considered as an essential pro-hormone in ovarian follicular steroidogenesis and synthesis (**Labrie, 2010**).

The 4 vinylcyclohexene (VCH) is the parent form of the compound, metabolized by cytochrome p450 enzymes to the diepoxide (VCD) which is the ovotoxic form of the chemical. VCD formation can occur in the liver, through enzymes expressed on the ovary that capable of this conversion (**Vo et al., 2012**).

Premature ovarian failure (POF) is premature ovarian insufficiency, is associated with amenorrhea, infertility, low estrogen, increased gonadotropin, and immature follicles before the age of 40, associated with the decline of the excess ovaries pool. Conventionally, in POF, the follicles do not develop properly (**Shahed and Young, 2013**).

The 4-vinylcyclohexene diepoxide (VCD) lead to POF in an experimental animal, the structure of in the ovarian follicle composed of a germ cell (oocyte) surrounded by somatic cells (granulosa and theca interna), oocytes formation (**Frye et al., 2012**). In the primordial follicle, oocytes are arrested at the prophase of the first meiotic division, and then form the full cohort of germ cells; the environmental chemicals destroy the primordial follicle pool dueto exposure chemicals VCD can lead to early menopause (**Chen et al., 2014**).

This study aimed to examine the replenishing effect of dehydroepiandrosteron (DHEA) on the reprotoxicity induced by exposure to vinylcyclohexene diepoxide (VCD) on mature female rats.

Materials and Methods

Chemicals:

The Dehydroepiandrosterone (DHEA) produced by MSD company, USA. Was dissolved in sesem oil, the dose was 0.2 ml/rat injected intraperitoneally, according to **Maayan et al. (2005)**. Vinylcyclohexene diepoxide (VCD) produced by MSD company, USA. Was dissolved in sesem oil, the dose was 1.2 ml/rat injected intraperitoneally, according to **Kao et al. (1996)**. Sesem oil was brought from El-Gomhoria Pharmaceutical Chemicals Company.

Experimental animals:

48 female mature sparagedawely rats weighting 200 ± 10 gm were obtained from the laboratory animal unit, Zagazig University, Egypt. The animals were clinically healthy, kept under hygienic condition, group housed in plastic cages with hard wood shavings as bedding. They were maintained on standard diet for the experimental period. ad-libitum supply of water and feed were maintained throughout the experimental period. Around one week before the experimental started the animals became accustomed to the laboratory conditions. In compliance with the institutional animal care guidelines, all studies are performed in animal facilities at the Faculty of Veterinary Medicine, University of Zagazig.

Experimental design:

48 mature female rats were divided into four groups: each group housed in separate cages throughout the experimental period. The First group as control group were injected intraperitoneally with sesame oil (0.2 ml) daily for 45 days, the second group were injected with DHEA (0.2 ml) once daily for 45 days, the third group were injected with VCD (1.2 ml) once daily for 45 days, the fourth group were injected with DHEA (0.2 ml) + VCD (1.2 ml) once daily for 45 days. After that all individuals were scarified. Then serum samples from each rat were collected for hormones (progesterone, estrogen, DHEA, FSH, LH, insulin and cortison) and enzymes activity measurements (GPX, SOD, MDA, CAT and GSH). The ovaries will be collected, and then preserved in 40% formalin solution for histological study.

Hormone measurements:

Hormones were measured in the serum collected after sacrificing the animals from the different experimental groups: Progesterone, Estrogen, Follicle Stimulating Hormone, Lutenizing Hormone, Insulin, Corticosterone, Dehydroepiandrosterone Hormone. The kit purchased by Cusabio Company, USA, was tested with the ELISA.

Histopathological evaluation:

After anaesthetizing by ether inhalation, then rat ovaries was surgically removed and flushed with phosphate buffer saline (PBS, pH 7.4 and fixed in neutral buffered formaldehyde for at least 48 hours). Include the dehydration by upward levels of ethanol, clearing in three xylene-changing and the melted paraffin finished with a 65 °C paraffin-wax embedding technique for the set samples. Four μm thick sections were stained by Hematoxylin and Eosine (H&E). Micrographs of the parts were taken with a digital camera (Leica EC3) connected to the microscope (Leica, DM500), which is the method defined by **Bancroft and Layton (2013)**.

Statistical analysis:

The normality of the data was tested using the Shapiro-Wilk test. All data were normally distributed. The data are represented as mean \pm standard error of mean (SEM). The data were analyzed by one-way analysis of variance (ANOVA) test. The data of different groups were compared by two-way ANOVA using the general linear model (GLM). All statistical analyses were performed in IBM SPSS (version 25) (**Tello and Crewson, 2003**).

Results**Hormones levels:**

From figure (1) we notice that the DHEA treated females was close to the control rats in most of the measured plasma hormone levels, except for hormonal the DHEA and CORT where the concentration was increased significantly ($P < 0.05$) as compared to its levels in control rats. While the group treated with VCD recorded a significant decrease ($P < 0.05$) in most of the hormones (P4, E2, FSH, LH, INS and DHEA) except for CORT hormone, which was significantly higher ($P < 0.05$) in this group compared to the control group, and shows no significant changes between FSH and LH in all groups. It should be noted that the gradual improvement that occurred as a result of giving DHEA to females treated with VCD in the levels of all hormones as compared with control rats.

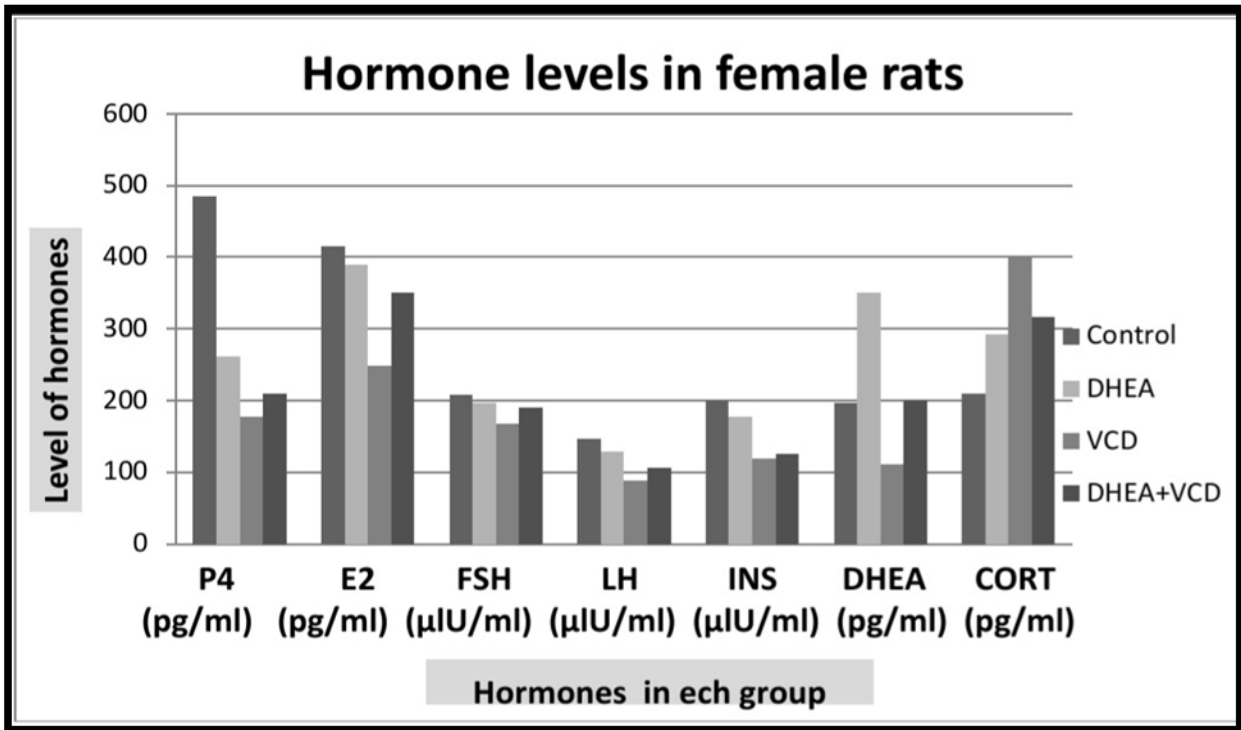


Figure (1): Progesterone, estrogen, follicle stimulating hormone, luteinizing hormone, insulin, dehydroepiandrosterone, corticosterone levels in control and treatment female groups.

P4 (progesterone), E2 (estrogen), FSH (follicle stimulating hormone), LH (luteinizing hormone), INS (insulin), DHEA (dehydroepiandrosterone), CORT (corticosterone).

DHEA (dehydroepiandrosterone group), VCD (Vinylcyclohexene diepoxide).

Histopathological evaluation:

Figure (2) shows histopathological examination of female rat ovaries in control group normal primordial follicle with owl eye nuclei. VCD group revealed atrophied primordial follicle with pyknotic nuclei. DHEA group revealed normal primordial follicle with owl eye nuclei. DHEA+VCD group showing hypertrophied primordial follicle with pyknotic nuclei and normal primary follicle with owl eye nuclei.

The DHEA-exposed rat showed an increasing number of cystic follicles in the ovaries, cystic follicles in a DHEA-exposed rats showed a thicker theca cell layer in representative sections from ovaries of VCD treated rats and showed a markedly higher level of collagen, especially in regions around the follicles.

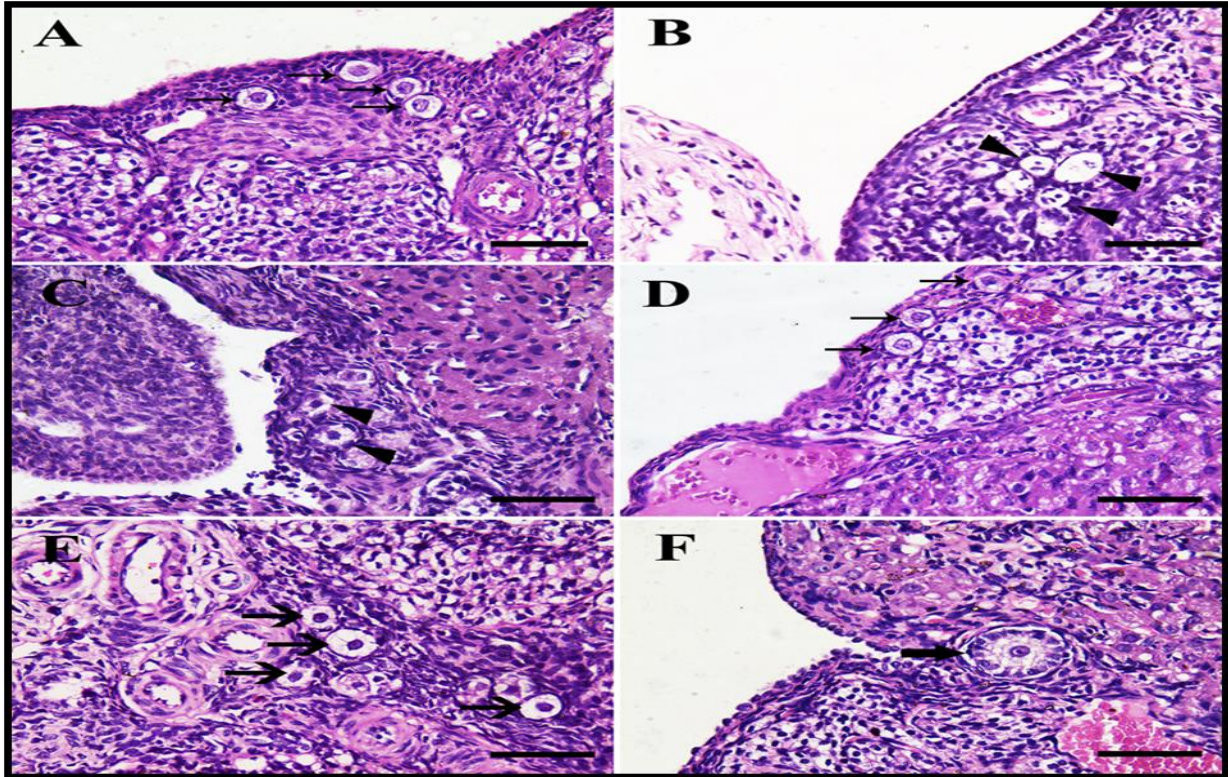


Figure (2): Histopathological examination of female rat ovaries

A: Control group showing normal primordial follicle with owl eye nuclei (arrows). B and C: VCD group revealing atrophied primordial follicle with pyknotic nuclei (arrowheads). D: DHEA group revealing normal primordial follicle with owl eye nuclei (arrows). E: DHEA+VCD group showing hypertrophied primordial follicle with pyknotic nuclei (arrows). F: DHEA+VCD group revealing normal primary follicle with owl eye nuclei (thick arrow). Scale bar = 50 μ m.

Discussion

The present study showed that serum DHEA significantly increased after DHEA administration in the female rats. These results coincide with the results of **Panjari and Davis (2007)** who suggested that the female treated with DHEA daily for 2 months showed significant increases of serum DHEA.

Liu et al. (2013) also confirmed this result after administration of the DHEA in treated group, the maximal content was increased and the maximal content of E also increased compared to control. The increase of concentration of serum androgens after DHEA administration is larger than concentration of serum estrogen in females, these results indicated that DHEA treated female rats predominantly led to formation of androgen but not estrogen.

DHEA treatment leads to increasing FSH receptors levels at early stages of folliculogenesis and important for recruitment of follicles and development which is detected by increase of level of serum FSH after DHEA administration. According to the two cell-two gonadotrophin theory, the androgens play role in adequate steroidogenesis in follicles. Thus, DHEA is important precursor steroid to synthesis of the sex steroid and is changed to androgens or estrogens. The estrogens stimulate the ovaries and increase growth of the follicles and proliferation of granulosa

cell and development, the estradiol concentration increased significantly in rats received DHEA (Sunkara et al., 2012).

Androgens are important and necessary precursors for estrogens biosynthesis in the ovaries, adrenal gland, and peripheral tissues (Thomas et al., 2018). Adrenal insufficiency is associated with abnormal, low or no serum concentrations of DHEA and DHEAS. Adrenal insufficiency is associated with decreased FSH, LH, estrogen and cortisol levels (Feuerstein et al., 2012).

In hypothalamic functions have been estimated VCD treated female rats with decreasing in LH surge magnitude is due to defect in neuroendocrine function, impaired function of ovaries or both. Due to the preovulatory raising in concentration of circulating estradiol (E2) consider as the functional trigger for the LH surge, age-related changes in E2 production due to decreased gonadotropin secretion during the afternoon of proestrus, the potential role of changed E2 levels in defected neuroendocrine function is not clear (DeVet et al., 2002).

In the hypothalamic-pituitary-ovarian axis of regulation, gonadotropin releasing hormone (GnRH) released by the hypothalamus stimulates the pituitary to secrete luteinizing hormone (LH) and follicle stimulating hormone (FSH). The observed ovotoxicity with VCH/VCD was due to direct ovarian targeting or due to impairment in hypothalamic-pituitary signaling (Hannon and Flaws, 2015).

The hormones of ovaries (17β -estradiol, progesterone and inhibin) have negative feedback on GnRH and LH/FSH. Thus, it was reasoned that if VCH/VCD targets the hypothalamus/pituitary, LH/FSH levels decreased. Several studies have used chemical VCD associated with cessation of hormone secretion (Okeke et al., 2013).

The hypothalamic-pituitary-adrenal axis influences and interactions between three endocrine glands the hypothalamus, the pituitary and the adrenal glands for maintaining several organ functions. Any defect in the function of this axis lead to secondary adrenal insufficiency associated with decreased corticotropin releasing hormone and adrenocorticotrophic hormone secretion from the hypothalamus and pituitary gland (Al-Aridi et al., 2011).

Administration of DHEA causes increasing receptors of FSH at early stages of folliculogenesis for follicular recruitment and development with the Significant increase of serum FSH level (Sunkara et al., 2012). Ovarian hormones (17β -estradiol, progesterone, inhibin) stimulate a negative feedback on GnRH and LH/FSH. Thus, it was reasoned that if VCH/VCD targets the hypothalamus/pituitary, LH/FSH levels decline, chemical induction (VCD) causes hormone secretion cessation (Okeke et al., 2013).

In this study, histological examination of female rat ovaries showing normal primordial follicle with owl eye nuclei in controlled group. VCD treated group revealing atrophied primordial follicle with pyknotic nuclei. DHEA treated group revealing normal primordial follicle with owl eye nuclei. DHEA+VCD treated group showing hypertrophied primordial follicle with pyknotic nuclei and revealing normal primary follicle with owl eye nuclei.

These results coincide with the results of Cason et al. (2000) showed normal follicles (primordial, primary and growing) in ovaries the control group, the DOR developed with VCD, decline in the number of follicles were occurred in the ovary compared to the control ovary. In all groups the number of follicles increased significantly after DHEA administration and the atresia rates were decreased in all three types of follicles in VCD treated group.

DHEA supplementation is one of the treatments for patients with DOR. In past studies on DHEA affects on ovaries, follicle recruitment and follicular growth a synergistic effect between DHEA and gonadotropins, **Barad and Gleicher (2006)** detected improved embryo quality and number of embryos available increased in patients with DOR after an average of 17 weeks of DHEA use (**Wiser et al., 2010**).

The DHEA-exposed rat showed an increasing number of cystic follicles in the ovaries, cystic follicles in a DHEA-exposed rats showed a thicker theca cell layer in representative sections from ovaries of VCD treated rats and showed a markedly higher level of collagen, especially in regions around the follicles.

In previous study on human fetal ovaries and adult ovaries has detected that fibrillin-3 observed at early in the development of human and fetal ovaries and decreased during gestation to very low concentration (**Hatzirodos et al., 2011**). However, fibrillin-3 is presented in the perifollicularstroma of primordial and primary follicles and this glycoprotein found in all connective tissues and increased after administration DHEA.

Conclusion

From present study it could be concluded that administration of DHEA to female rat affecting on reproductive function, it is important precursor steroid to synthesis of the sex steroid and is changed to androgens or estrogens. The estrogens stimulate the ovaries and increase growth of the follicles and proliferation of granulosa cell and development

تأثير تجديد مادة ديهيدرو إيبي أندروستيرون على سمية المبيض الناجمة عن التعرض لمادة ثنائي أكسيد الفينيل سيكلوهكسين في إناث الفئران الناضجة

عادل عبدالنواب البدري* ، صلاح فرج خميس** ، نوره ابراهيم الزاعل***

*قسم الفسيولوجي - كلية الطب البيطري - جامعة الزقازيق - مصر.

**قسم الفسيولوجي - كلية الطب البيطري - جامعة عمر المختار - البيضاء.

***قسم علم الحيوان - كلية العلوم - جامعة عمر المختار - البيضاء.

إن تجريب هرمون ديهيدرو إيبي أندروستيرون (DHEA) للإناث كان له تأثيرات إيجابية على استجابة المبيض، احتياطي المبيض، جودة إنتاج الأجنة من البويضات، معدل الحمل التراكمي، معدل المواليد الأحياء، وكذلك تحسين معدل الإجهاض وتحسين نتائج علاج العقم. الهدف من هذه الدراسة هو فحص تأثير تجديد مادة ديهيدرو إيبي أندروستيرون (DHEA) على السمية الناتجة عن التعرض لثنائي أكسيد الفينيل سيكلوهكسين (VCD) على إناث الفئران الناضجة. تم تقسيم 48 أنثى ناضجة إلى أربع مجموعات متساوية. تم حقن مجموعة التحكم داخل الصفاق بزيت السمسم (0.2 مل) يوميا لمدة 45 يوما. تم حقن المجموعة الثانية بـ DHEA (0.2 مل) مرة واحدة يوميا لمدة 45 يوما. المجموعة الثالثة تم حقنها بـ VCD (1.2 مل) مرة واحدة يوميا لمدة 45 يوما. تم حقن المجموعة الرابعة بـ DHEA (0.2 مل) + VCD (1.2 مل) مرة واحدة يوميا لمدة 45 يوما. أظهرت النتائج أن الإناث المعالجة بـ DHEA كانت قريبة من الفئران الضابطة في معظم مستويات هرمونات البلازما المقاسة، باستثناء هرموني DHEA و CORT. بينما سجلت المجموعة المعالجة بـ VCD انخفاضا معنويا ($P < 0.05$) في معظم الهرمونات (E2 و P4 و FSH و LH و INS و DHEA) باستثناء هرمون CORT. وتجدر الإشارة إلى التحسن التدريجي الذي حدث نتيجة إعطاء DHEA للإناث المعالجة بـ VCD في مستويات جميع الهرمونات مقارنة بالفئران الضابطة. الفحص النسيجي المرضي لمبيض إناث الفئران في مجموعة VCD يظهر ضمور الجريب البدائي مع نوى متجمدة. تكشف مجموعة DHEA عن جريب بدائي طبيعي مع نوى عين البومة. مجموعة (DHEA+VCD) تكشف عن الجريب الأساسي الطبيعي مع نوى عين البومة. من

الدراسة الحالية يمكن استنتاج أن إعطاء DHEA إلى أنثى الجرذان يحسن الوظيفة الإنجابية ، ومن المهم وجود السلانف الستيرويدية لتخليق الستيرويد الجنسي ويتم تغييره إلى الأندروجينات أو الإستروجين. يحفز هرمون الاستروجين المبايض ويزيد من نمو الجريبات وتكاثر الخلايا الحبيبية وتطورها. الكلمات المفتاحية: ديهيدرو إيبي أندروستيرون ، ثنائي أكسيد الفينيل سيكلوهكسين ، الجهاز التناسلي ، الهرمونات الجنسية ، إناث الجرذان.

References

1. Ahn, H., An, B., Jung, E., Yang, H., Choi, K. and Jeung, E. B. (2012): Parabens inhibit the early phase of folliculogenesis and steroidogenesis in the ovaries of neonatal rats. *Mol. Reprod. Dev.*, 79: 626–636.
2. Al-Aridi, R., Abdelmannan, D. and Arafah, B. (2011): Biochemical diagnosis of adrenal insufficiency: the added value of dehydroepiandrosterone sulfate measurements. *Endocr. Pract.*, 17(2): 261–270.
3. Auchus, R. (2004): The backdoor pathway to dihydrotestosterone. *Trends Endocrinol Metab.*, 15: 432-438.
4. Bancroft, J. and Layton, C. (2013): The Hematoxylin and eosin. In: Suvarna S. K, Layton C, Bancroft J. D, editors. *Theory Practice of histological techniques*. 7th ed. Ch. 10 and 11. Philadelphia: *Churchill Livingstone of El Sevier*; pp. 179–220. *Res.* 49(6): 685-693.
5. Barad, D. and Gleicher, N. (2006): Effect of dehydroepiandrosterone on oocytes and embryo yields, embryo grade and cell number in IVF. *Hum Reprod* 21: 2845–9.
6. Casson, P., Lindsay, M., Pisarska, M., Carson, S. and Buster, J. (2000): Dehydroepiandrosterone supplementation augments ovarian stimulation in poor responders: A case series. *Hum. Reprod.*, 15: 2129–32.
7. Chen, H., Perez, J. N., Constantopoulos, E., McKee, L., Regan, J., Hoyer, P. B., Brooks, H. L. and Konhilas, J. (2014): A method to study the impact of chemically-induced ovarian failure on exercise capacity and cardiac adaptation in mice. *J. Vis. Exp.*, (86): e51083.
8. DeVet, A., Laven, J. S., de Jong, F. H., Themmen, A. P. and Fauser, B. C. (2002): Antimullerian hormone serum levels: a putative marker for ovarian aging. *Fertil. Steril.*, 77: 357-362.
9. Feuerstein, P., Puard, V., Chevalier, C., Teusan, R., Cadoret, V. and Guerif, I. (2012): Genomic assessment of human cumulus cell marker genes as predictors of oocyte developmental competence: impact of various experimental factors. *PLoSOne*, 7: 404-49.
10. Frye, J. B., Lukefahr, A. L., Wright, L. E., Marion, S. L., Hoyer, P. B. and Funk, J. L. (2012): Modeling perimenopause in sprague-dawley rats by chemical manipulation of the transition to ovarian failure. *Comp. Med.*, 62: 193–202.
11. Gandhi, J., Chen, A. and Dagur, G. (2016): Genitourinary syndrome of menopause an overview of clinical manifestations, pathophysiology, etiology, evaluation, and management. *Am. J. Obstet. Gynecol.*, 215: 704-711.

12. Hannon, P. R. and Flaws, J. A. (2015): The effects of phthalates on the ovary. *Front. Endocrinol.*, 6: 8.
13. Hashimoto, K. (2013): Sigma-1 receptor chaperone and brain-derived neurotrophic factor: Emerging links between cardiovascular disease and depression. *Prog. Neurobiol.*, 100: 15-29.
14. Hatzirodos, N., Bayne, R., Irving-Rodgers, H., Hummitzsch, K., Sabatier, L., Lee, S., Bonner, W., Gibson, M., Rainey, W. and Carr, B. (2011): Linkage of regulators of TGF-beta activity in the fetal ovary to polycystic ovary syndrome. *FASEBJ*, 25: 2256–2265.
15. Kao, S., Sipes, I. and Hoyer, P. (1996): Early effects of ovotoxicity induced by 4-vinylcyclohexene diepoxide in rats and mice. *Reprod. Toxicol.*, 13: 67-75.
16. Labrie, F., Martel, C. and Bélanger, A. (2017): Androgens in women are essentially made from DHEA in each peripheral tissue according to intracrinology, 168: 9-18.
17. Labrie, F. (2010): DHEA, important source of sex steroids in men and even more in women. *Prog. Brain Res.*, 182: 97-148.
18. Liu, T. C., Lin, C. H., Huang, C. Y., Ivy, J. L. and Kuo, C. H. (2013): Effect of acute DHEA administration on free testosterone in middle-aged and young men following high-intensity interval training. *European journal of applied physiology*, 113: 1783–1792.
19. Maayan, R., Morad, O., Dorfman, P., Overstreet, D., Weizman, A. and Yadid, G. (2005): The involvement of dehydroepiandrosterone (DHEA) in blocking the therapeutic effect of electroconvulsive shocks in an animal model of depression. *EurNeuropsychopharmacol*, 15(3): 253-62.
20. Okeke, T., Anyaehie, U. and Ezenyeaku, C. (2013): Premature menopause. *Ann. Med. Health Sci. Res.*, 3: 90–95.
21. Panjari, M. and Davis, S. (2007): DHEA therapy for women: effect on sexual function and wellbeing. *Human Reproduction Update*, 13: 239–248.
22. Shahed, A. and Young, K. A. (2013): Anti-mullerian hormone (AMH), inhibin-alpha, growth differentiation factor 9 (GDF9), and bone morphogenic protein-15 (BMP15) mRNA and protein are influenced by photoperiod-induced ovarian regression and recrudescence in siberian hamster ovaries. *Mol. Reprod. Dev.*, 80: 895–907.
23. Sunkara, S., Coomarasamy, A., Arlt, W. and Bhattacharya, S. (2012): Should androgen supplementation be used for poor ovarian response in IVF? *Hum. Reprod.*, 27: 637–40.
24. Tan, O., Bradshaw, K. and Carr, B. (2012): Management of vulvovaginal atrophy-related sexual dysfunction in postmenopausal women: an up-to-date review. *Menopause*, 19: 109-117.
25. Tello, R. and Crewson, P. E. Hypothesis testing II: means. *Radiol.*, (2003); 227(1): 1-4.
26. Thomas, P., Converse, A. and Berg, H. (2018): A novel membrane androgen receptor and zinc transporter protein. *Gen. Comp. Endocrinol.*, 257: 130-136.

-
27. Tsui, K., Lin, L., Chang, R., Huang, B., Cheng, J. and Wang, P. (2014): Effect of dehydroepiandrosterone supplementation on women with poor ovarian response. *77*: 505-507.
28. Vo, T., An, B., Yang, H., Jung, E., Hwang, I. and Jeung, E. (2012): Calbindin-D9K as a sensitive molecular biomarker for evaluating the synergistic impact of estrogenic chemicals on GH3 rat pituitary cells. *Int. J. Mol. Med.*, *30*: 1233–1240.
29. Wisner, A., Gonen, O., Ghetler, Y., Shavit, T., Berkovitz, A. and Shulman, A. (2010): Addition of dehydroepiandrosterone (DHEA) for poor-responder patients before and during IVF treatment improves the pregnancy rate: A randomized prospective study. *Hum. Reprod.*, *25*: 2496–2500.